

Minimally invasive hysterectomy in Coatis (*Nasua nasua*)¹

Bruno W. Minto^{2*}, Claudia E. Nagatsuyu², Carlos R. Teixeira³, Felipe S. Zanuzzo³,
Thaísa D. Candido³, Lucia M.I. Diogo³ and Aline S. Macedo²

ABSTRACT.- Minto B.W., Nagatsuyu C.E., Teixeira C.R., Zanuzzo F.S., Candido T.D., Diogo L.M.I. & Macedo A.S. 2017. **Minimally invasive hysterectomy in Coatis (*Nasua nasua*).** *Pesquisa Veterinária Brasileira* 37(6):627-629. Departamento de Clínica e Cirurgia Veterinária, Faculdade de Ciências Agrárias e Veterinárias, Universidade Estadual Paulista, Via de Acesso Prof. Paulo Donato Castellane s/n, Vila Nova Aparecida, Jaboticabal, SP 14884-900, Brazil. E-mail: brunobtu@yahoo.com.br

Some wildlife species, such as coatis, have a high degree of adaptability to adverse conditions, such as fragmented urban forests, increasingly common on the world stage. The increase in the number of these mesopredators causes drastic changes in the communities of smaller predators, interferes with reproductive success of trees, as well as becoming a form of exchange between domestic and wild areas, favoring the transmission of zoonosis and increasing the occurrence of attacks to animals or people. This report describes the use of minimally invasive hysterectomy in two individuals of the species *Nasua nasua*, which can be accomplished through the use of hook technique, commonly used to castrate dogs and cats. The small incision and healing speed of incised tissues are fundamental in wild life management since the postoperative care is limited by the behavior of these animals. This technique proved to be effective and can greatly reduce the morbidity of this procedure in coatis.

INDEX TERMS: *Nasua nasua*, coatis, hysterectomy, castration, minimally invasive surgery, wild animals.

RESUMO.- [Histerectomia minimamente invasiva em Quatis (*Nasua nasua*).] Algumas espécies selvagens, como os quatis, possuem alto grau de adaptabilidade a condições adversas, como as de florestas urbanas fragmentadas, cada vez mais comuns no cenário mundial. O aumento do número destes mesopredadores causa alterações drásticas nas comunidades de pequenos predadores, interfere no sucesso reprodutivo de árvores, além de se tornar uma forma de intercâmbio entre áreas domésticas e selvagens, facilitando a veiculação de zoonoses e aumentando a ocorrência de ataques a animais ou pessoas. O presente relato descreve a utilização da histerectomia minimamente invasiva em dois indivíduos da espécie *Nasua nasua*, que pode ser realizada por meio da utilização da técnica do gancho, comumente uti-

lizada para a castração de cães e gatos. A incisão reduzida e a rapidez da cicatrização dos tecidos incisados são fundamentais no manejo de espécies selvagens, visto que os cuidados pós-operatórios são limitados pelo comportamento desses animais. Esta técnica mostrou-se eficaz e pode reduzir sobremaneira a morbidade desse procedimento em quatis.

TERMOS DE INDEXAÇÃO: *Nasua nasua*, quatis, histerectomia, castração, cirurgia minimamente invasiva, animais selvagens.

INTRODUCTION

Coatis are gregarious carnivores, essentially diurnal, terrestrial and arboreal animals (Beisiegel 2001) that belong to the Family Procyonidae. There are four recognized species: White-nosed coati (*Nasua narica*), South America or Ring-Tailed Coati (*Nasua nasua*), Wedel Coati (*Nasua wedelli*) and Mountain Coati (*Nasuella olivacea*). *Nasua nasua* is found in tropical regions of South America, except Chile, in the Amazon, Cerrado, Caatinga, Pantanal, Atlantic Rainforest and Southern Plains (Cheida et al. 2006).

The fragmentation of forests may cause the extinction of top predators and lead to a density increase of medium-sized generalist species which can result in drastic changes, in the small vertebrate communities (Crooks & Soulé

¹ Received on June 15, 2015.

Accepted for publication on September 19, 2016.

² Departamento de Clínica e Cirurgia Veterinária, Faculdade de Ciências Agrárias e Veterinárias (FCAV), Universidade Estadual Paulista (Unesp), Campus Jaboticabal, Via de Acesso Prof. Paulo Donato Castellane s/n, Vila Nova Aparecida, Jaboticabal, SP 14884-900, Brazil. *Corresponding author: limacedo@gmail.com

³ Departamento de Cirurgia e Anestesiologia Veterinária, Faculdade de Medicina Veterinária e Zootecnia (FMVZ), Unesp, Campus Botucatu, Distrito Rubião Jr s/n, Botucatu, SP, 18618-000, Brazil.

1999). Coatis are highly adaptable animals, a fact that leads to overpopulation and its related problems (Beisiegel 2001). This occurs especially in protected forest areas where it results in conflicts with humans and other wild animals and favors the transmission of zoonosis, as well. Thus, control of the population in conflict areas should become accessible and feasible (Francioli et al. 2007).

The reproductive management of wild animals is considered experimental due to the lack of scientific reports on the subject. Many of the techniques available for reproductive management of carnivores in zoos have been extensively tested in domestic animals because they are an excellent experimental model for pilot studies (Gobello & Corrada 2002). Castration certainly is the best method available for population control of domestic animals and the most used in veterinary medicine since it avoids euthanasia and prevents the risk of diseases that result from the use of contraceptive drugs.

Minimally invasive ovariohysterectomy is considered ideal for group castration of bitches and cats; it avoids long hospitalization thus reducing procedure costs and patient stress. Both the small incision and the fast tissue-healing process are fundamental since the post-operative care is limited by the behavior of wild species. The non-laparoscopic techniques follow the principle of small incisions and reducing the post-operative discomfort without, however, requiring laparoscopic equipment (Pukacz et al. 2009). An example is the technique that instead of using the hemostatic forceps uses the ovary fishing hook.

This report describes the minimally invasive hysterectomy of two coatis *N. nasua*. The procedure was performed on two healthy females aged 18 months that came from a Municipal Park Zoo.

CASE REPORT

An association of the drugs ketamine (10mg/kg), midazolam (0.2mg/kg) and morphine (0.3mg/kg) was injected intramuscularly as pre-anesthesia. After 10 minutes, a peripheral vein was cannulated to inject propofol (4mg/kg) to allow endotracheal intubation (Fig.1A). After intubation, the animals were connected to a rebreathing system for administering isoflurane in 100% oxygen.

The animals were previously prepared for aseptic surgery of the ventral abdominal region. A caudal skin incision of approximately 1cm was performed 3cm from the umbilicus (Fig.1B). Subsequently, the ovarian pedicle and its junction with the right uterine horn were located using an ovariosalpingohysterectomy (OSH) hook. The junction between the ovary and the uterine horn was ligated with a suture loop using 2-0 nylon thread, keeping the ovary. The same procedure was performed between the ovary and the contralateral uterine horn. The uterus (Fig.1C) was located through the uterine bifurcation, and it was transfixed with 2-0 nylon thread. The abdominal wall was sutured with a cruciate mattress pattern, followed by a simple interrupted suture in the skin (Fig.1D).

At the end of surgery, a combination of cephalothin (22mg/kg) and meloxicam (0.2mg/kg) was injected intravenously. The animals were housed in individual pens where feed and water were offered *ad libitum*. They were kept in the pens until the stitches were removed 10 days after the operation. The females were discharged and returned to zoo life, where they had contact with male specimens without any reported behavior change. There was no incompatibility nor aggression within the group.

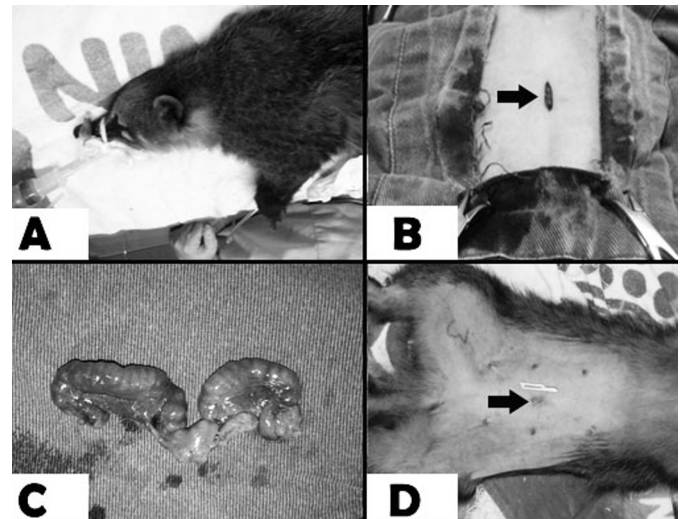


Fig.1. (A) Coati (*Nasua nasua*) with endotracheal intubation before surgical procedure. (B) Skin incision (arrow) of approximately 1cm performed 3cm from the umbilicus of the Coati (*N. nasua*). (C) Uterine horns surgically removed. (D) Postoperative picture of the Coati (*N. nasua*) with the skin incision (arrow) closed with simple interrupted suture. Note the nr 11-scalpel blade beside the skin incision for comparison.

The project was submitted and approved by the Ethics Committee on Animal Use - CEUA under protocol number 017819/14.

DISCUSSION

The presence of wild animals in urban areas is a dilemma discussed all over the world due to both predation and pathogen transmission threats. Coati is not in the list of endangered animals of IBAMA- (the Brazilian Institute for the Environment and Renewable Natural Resources). On the contrary, it is a common species frequently seen since they are well adaptable and capable of adjusting their foraging preferences to different environmental conditions (Beisiegel 2001). Surgical sterilization is most often performed in bitches and cats; however, there are few reports of surgical techniques used in wild animals. Therefore, it is timely to conduct research on this topic. Comparison between coatis and domestic dogs can be made based upon common characteristics found in the animals from the *procyonidae* family such as morphological characteristics of the mammary glands (Casals et al. 2013) and teeth (Pieri et al. 2011).

The ovarian pedicle and uterine horns were located using the OSH hook, thus allowing a small incision. The conventional ovariohysterectomy technique was used in agouti with satisfactory results (Martins 2009). Compared to the conventional, this minimally invasive technique has potential advantages, including reduced pain, lower risk of dehiscence of the stitches and hemorrhage (Davidson et al. 2004), shorter and better recovery time and lower physiological stress response (Nimwegen 2007). The minimally invasive non-laparoscopic technique has the advantage of not requiring expensive equipment. Absorbable or non-absorbable sutures or titanium clamps are available as hemostatic methods for hysterectomy surgery in small animals. In this study nylon suture was used to ligate the

uterine horns without complications. Non-conventional suture materials such as nylon tie-raps have been reported as hemostatic methods in dogs but can cause severe complications and are not recommended for surgeries in exotic animals (Macedo et al. 2012). A recent British study evaluated the levels of concern and complications that new graduated veterinarians had regarding female dogs spaying in the first year of veterinary practice. Spaying is a common surgical technique but new graduates require supervision during the first 6 months of veterinary practice to master the technique, that can have serious complications if mis-conducted (Blacklock et al. 2016). Both surgeries in this study were performed by a veterinary surgeon with more than 5 years of veterinary practice and clinical experience with wild animals.

Unlike the technique in which the ovary is removed along with the uterine horns (Davidson et al. 2004, Martins 2009), in this report we decided to keep the ovaries to avoid changes in the social behavior of the animals. Additionally, the ovariectomy in female rats induced a positive energy balance by increasing the weight gain while reducing the activity level (Giles et al. 2010), and, reducing the activity level of a wild coati used to a free life would make the animal obese and an easy prey, as well. The animals from this study went back to zoo life without any signs of aggression or rough interaction with the male specimens. Other types of contraception methods such as melengestrol acetate implants have serious consequences such as pyometra and uterine adenocarcinoma already reported in coatis (Chittick et al. 2001).

Furthermore, the coati is a gregarious animal and the decrease in estrogen levels resulting from the ovariectomy could interfere in the socio/sexual hierarchy of the group. Exogenous administration of estrogen (E2) in dominating Rhesus monkey females increases the directed sexual behavior of the males while the subordinate females present mitigating effects of estrogen on sexual behavior (Reding et al. 2012). In groups of naked-mole-rats, it was observed a reduction in the nose rubbing, behavior normally displayed only by the dominant couples after ovariectomy. Such behavior may reinforce the specific reproductive connection of male and female leaders of the group; however, it is not clear whether the decrease has biological significance (Goldman et al. 2006).

To the authors opinion there is no long-term health risks to the coatis due to the hysterectomy. In a previous study, there was no differences in hormone concentrations observed in hysterectomized dogs compared to the control group. Progesterone, oestradiol, prolactin and growth hormone maintained basal levels, despite uterus removal. Hysterectomy only caused a shortened period in anoestrous interval between groups (Hoffmann et al. 1992). Unilateral hysterectomy has also been reported in bitches without health compromise (Seyrek-Intas et al. 2004)

However, the two animals had no complications during the postoperative, and after 10 days the surgical wound was completely healed. Likewise, surgical wound healing without serious complications was reported for bitches undergoing minimally invasive ovariectomy (Pukacz et al. 2009).

CONCLUSIONS

Minimally invasive hysterectomy using the hook technique, commonly used for castration in bitches and cats, may be performed in coatis *Nasua nasua*.

This technique proved to be effective and may reduce coati morbidity during the procedure.

REFERENCES

- Beisiegel B.M. 2001. Notes on the coati, *Nasua nasua* (Carnivora: Procyonidae), in an Atlantic Forest area. *Braz. J. Biol.* 61(4):689-692.
- Blacklock K.L.B., Langer P., Halfacree Z., Yool D.A., Corr S., Owen L., Friend E. & Ekiri A. 2016. Canine Ovariectomy: A Survey of Surgeon Concerns and Surgical Complications Encountered by Newly Graduated Veterinarians. *J. Vet. Med. Educ.* 43(2):1-6.
- Casals J.B., Mançanares C.A., Pieri N.C.G., Miglino M.A., Ambrósio C.E. & Carvalho A.F. 2013. Morfologia da glândula mamária do quati (*Nasua nasua*). *Pesq. Vet. Bras.* 33(11):1371-1378.
- Cheida C.C., Nakano-Oliveira E., Fusco-Costa R., Rocha-Mendes F. & Quadros J. 2006. Ordem Carnivora, p.231-275. In: Reis N.R., Peracchi A.L., Pedro W.A. & Lima I.P. (Eds), *Mamíferos do Brasil*. Universidade Estadual de Londrina, Paraná.
- Chittick E., Rotstein D., Brown T. & Wolfe B. 2001. Pyometra and uterine adenocarcinoma in a melengestrol acetate-implanted captive coati (*Nasua nasua*). *J. Zoo. Wildlife Med.* 32(2):245-251.
- Crooks K.R. & Soulé M.E. 1999. Mesopredator release and avifaunal extinctions in a fragmented system. *Nature* 400(6744):563-566.
- Davidson E.B., Moll H.D. & Payton M.E. 2004. Comparison of laparoscopy ovariectomy and ovariectomy in dogs. *Vet. Surg.* 33(1):62-69.
- Francioli A.L.R., Cota G.M., Mançanares C.A.F., Martins D.S., Ambrosio C.E., Miglino M.A. & Carvalho A.F. 2007. Morfologia dos órgãos genitais masculinos em quatis (*Nasua nasua* Linnaeus, 1766). *Biotemas* 20(1):27-36.
- Giles E.D., Jackman M.R., Johnson G.C., Schedin P.J., Houser J.L. & Maclean P.S. 2010. Effect of the estrous cycle and surgical ovariectomy on energy balance, fuel utilization, and physical activity in lean and obese female rats. *Am. J. Physiol. Regul. Integr. Comp. Physiol.* 299(6):1634-1642.
- Gobello C. & Corrada Y. 2002. Control de la reproducción em carnívoros de zoológico. *Revta Invest. Vet. Perú* 13(1):1-5.
- Goldman S.L., Forger N.G. & Goldman B.D. 2006. Influence of gonadal sex hormones on behavioral components of the reproductive hierarchy in naked mole-rats. *Horm. Behav.* 50(1):77-84.
- Hoffmann B., Höveler R., Hasan S.H. & Failing K. 1992. Ovarian and pituitary function in dogs after hysterectomy. *J. Reprod. Fertil.* 96(2):837-845.
- Macedo A.S., Dal-Bó I.S., Quadros A.M., Brambatti G., Reis K.D.H.L., Brun M.V., Alievi M.M. & Beck C.D.C. 2012. Complications associated with ovariectomy using nylon tie-rap as an hemostatic method. *Acta Sci. Vet.* 40(4):1-5.
- Martins L.L. 2009. Ovariosalpingohisterectomia em cutias: técnicas anestésica e cirúrgica, análise morfológica uterina e microbiológica da vagina e do útero (*Dasyprocta azarae* Lichtenstein 1823). *Dissertação de Mestrado*. Faculdade de Ciências Agrárias e Veterinárias, Universidade Estadual Paulista, Jaboticabal, SP. 57p.
- Nimwegen S.A.V.K.J. 2007. Laparoscopic ovariectomy in cats: comparison of laser and bipolar electrocoagulation. *J. Feline Med. Surg.* 9(5):397-403.
- Pieri N.C.G., Mançanares C.A.F., Bertassoli B., Lima J.M.N., Thomaz J.M. & Carvalho A.F. 2011. Classificação morfofuncional dos dentes de quati, *Nasua nasua*. *Pesq. Vet. Bras.* 31(5):447-451.
- Pukacz M., Kienzie B. & Braun J. 2009. Simple, minimally invasive technique for ovariectomy in the dog. *Vet. Rec.* 165(23):688-690.
- Reding K., Michopoulos V., Wallen K., Sanchez K.M., Wilson M.E. & Toufexis D. 2012. Social status modifies estradiol activation of sociosexual behavior in female rhesus monkeys. *Horm. Behav.* 62(5):612-620.
- Seyrek-Intas K., Wehrend A., Nak Y., Tek H.B., Yilmazbas G., Gokhan T. & Bostedt H. 2004. Unilateral hysterectomy (cornuectomy) in the bitch and its effect on subsequent fertility. *Theriogenology* 61(9):1713-1717.